




DOI: <https://doi.org/10.17921/1415-6938.2025v29n1p105-114>

Renal Morphology and Vascularization in a Specimen of *Puma concolor* (Linnaeus, 1771)

Morfologia e Vascularização Renal em um Espécime de *Puma concolor* (Linnaeus, 1771)


Received on: 30/01/2025

Accepted on: 07/03/2025


Anieli Vidal Stocco: Universidade Federal Rural do Rio de Janeiro, Programa de Pós-Graduação em Medicina Veterinária. RJ, Brasil. E-mail: anielistocco@gmail.com 

Edmilla Pastor Marquez: Universidade Federal Rural do Rio de Janeiro. RJ, Brasil. 

Marcelo Salvador Gomes: Universidade Augusto Mota. RJ, Brasil. 

Carlos Augusto Santos-Sousa: Universidade Federal dos Vales do Jequitinhonha e Mucuri, Instituto de Ciências Agrárias. MG, Brasil. 

Paulo Souza Júnior: Laboratório de Anatomia Animal da UNIPAMPA, Uruguaiana. RS, Brasil. 

Marcelo Abidu-Figueiredo: Universidade Federal Rural do Rio de Janeiro, Departamento de Anatomia Animal e Humana, Laboratório de Ensino e Pesquisa em Morfologia dos Animais Domésticos e Selvagens. RJ, Brasil. 

Abstract

The cougar (*Puma concolor*) is the second-largest felid species in Brazil, found in some regions of North America and widely distributed throughout South America. Morphological studies involving wild felines are important as they contribute to understanding the ecological characteristics of a species. This study aimed to determine the renal morphometric variables and vascularization in a cougar. During the dissection performed in the laboratory, the morphology and renal vascularization of an adult female cougar specimen were observed. The kidneys had cranial and caudal extremities, lateral and medial margins (renal hilum), and dorsal and ventral surfaces. The kidneys were smooth on their surface, lacked lobulations, and exhibited symmetrical shape. They consisted of an external cortical region and an internal medullary region, with the renal pelvis and crest visible in longitudinal and transverse sections. They were simple and unipapillary. The right kidney measured 5.51 cm in length, 3.35 cm in width, and 3.50 cm in thickness. The renal artery was 3.79 cm long. Two renal veins were observed: the first, craniodorsal, measured 2.80 cm in length, and the second, caudoventral, measured 2.64 cm in length. The left kidney measured 5.39 cm in length, 3.22 cm in width, and 3.36 cm in thickness. The renal artery was 3.04 cm long. The renal vein was single, measuring 2.91 cm in length. The results contribute to the anatomical knowledge of the species, serving as a basis for comparative studies and applications in veterinary medicine and wildlife management.

Keywords: Anatomy. Wild Felines. Urinary System.

Resumo

A onça-parda (*Puma concolor*) é a segunda maior espécie de felídeo no Brasil, podendo ser encontrada em algumas regiões da América do Norte, estando amplamente distribuída em toda a América do Sul. Estudos morfológicos envolvendo felinos silvestres são importantes, pois contribuem para a compreensão das características ecológicas de uma espécie. O trabalho teve como objetivo determinar as variáveis morfológicas e vascularização renais em onça-parda. Durante a dissecação realizada no laboratório, observou-se a morfologia e vascularização renal em um espécime de onça-parda fêmea, adulta. Os rins apresentaram extremidades cranial e caudal, margem lateral e medial (hilo renal) e superfícies dorsal e ventral. Os rins eram lisos em sua superfície e desprovidos de lobações, apresentando simetria de forma. Os rins consistiam em uma região cortical externa e uma medular interna, com a pelve e a crista renal nos cortes longitudinal e transversal. Eram simples e unipilares. O rim direito apresentou 5,51 cm de comprimento, 3,35 cm de largura e 3,50 cm de espessura. A artéria renal apresentou 3,79 cm de comprimento. Verificou-se duas veias renais, a primeira, craniodorsal, apresentou 2,80 cm de comprimento e a segunda, caudoventral, apresentou 2,64 cm de comprimento. O rim esquerdo apresentou 5,39 cm de comprimento, 3,22 cm de largura e 3,36 cm de espessura. A artéria renal apresentou 3,04 cm de comprimento. A veia renal apresentou-se única, medindo 2,91 cm de comprimento. Os resultados obtidos contribuem para o conhecimento anatômico da espécie, podendo servir de base para estudos comparativos e aplicações na clínica veterinária e conservação.

Palavras-chave: Anatomia. Felinos Silvestres. Sistema Urinário.

1 Introduction

The cougar or puma is a large felid that reaches a body mass ranging from 30 to 100 kg and approximately two meters in length in adulthood (Sunquist; Sunquist, 2009). This terrestrial mammal has a broad geographical distribution, occurring from Canada to the southernmost regions of Chile (Azevedo *et al.*, 2013; Oliveira; Cassaro, 1999). The main threats to the cougar include predatory hunting and habitat alterations, which reduce prey availability (Oliveira; Cassaro, 1999). In Brazil, the species has been classified as vulnerable since 2014, according to the latest list of endangered animals compiled by the Chico Mendes Institute for Biodiversity Conservation (ICMBio).

Morphological studies involving wild felids are crucial as they contribute to understanding the ecological characteristics of a species. Additionally, anatomy, one of the oldest biomedical sciences, is an essential tool for addressing questions related to species biology and evolution, particularly concerning interactions involving habitat environment, feeding, and reproductive adaptations.

Each kidney has cranial and caudal poles, medial and lateral borders, and dorsal and ventral surfaces. The convex lateral border connects the cranial and caudal poles. The medial border contains an indentation (hilum) that defines the renal sinus. The renal sinus contains the ureter, renal artery, renal vein, lymphatic vessels, and nerves. Among these structures, the renal artery is the most dorsal, while the renal vein is the most ventral (Evans; De Lahunta, 2013). Typically, in most species, the right renal artery is positioned more cranially than the left due to the relatively more cranial position of the right kidney (Nickel ; Schummer; Seiferle, 1981).

Knowledge of reference values for kidney measurements can aid in diagnosing various renal diseases. Alterations in these measurements may indicate nephropathies due to hypertrophic

processes and/or atrophy (Beland *et al.*, 2010; Yamashita *et al.*, 2015). Therefore, it is imperative to establish a standard for typical renal measurements in each species. Necropsy studies in humans suggest that variations in kidney size and weight are sex-related, with larger kidneys observed in males. The left kidney is known to be larger than the right, regardless of sex (Moell, 1956). However, this information remains unclear in wild animals. Jarreta, Bombonato, and Guimarães (2004) evaluated the kidneys of the small-spotted cat using ultrasonography and found no differences in measurements between antimers or between sexes. Similar findings were reported in the serval (*Leptailurus serval*) by Hespel, Leon, and Duval (2019).

Despite the increase in both basic and applied research involving wild animals, anatomical studies describing renal anatomy and vascularization in these species remain scarce. However, concerning morphology, a limited number of studies have demonstrated that acquiring anatomical information is crucial for future research and for species conservation in captivity or natural habitats. Therefore, this study determined the morphometric variables of the kidneys and renal vessels in the cougar and compared the data, with an emphasis on the order Carnivora.

2 Material and Methods

The article derives from the project "Basic and Applied Research in the Morphology of Wild and Exotic Animals," which was submitted and approved by the Ethics Committee on Animal Use (CEUA) (No. 018/2017).

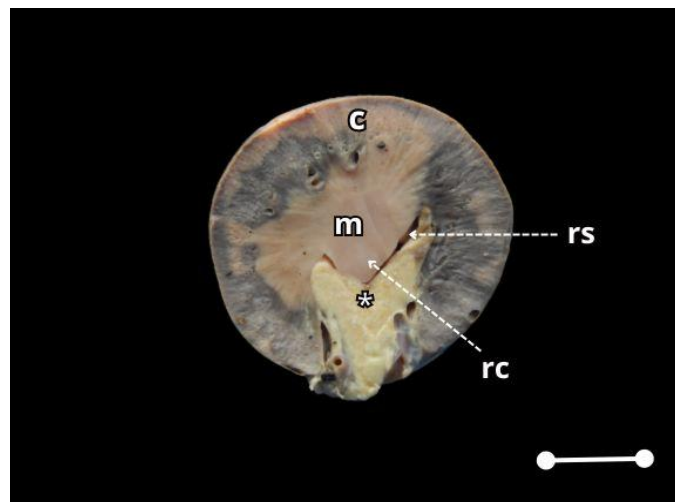
During dissection activities conducted at the Laboratory of Teaching and Research in Morphology of Domestic and Wild Animals (LEPeMADS) of the Department of Animal and Human Anatomy at the Federal Rural University of Rio de Janeiro, the renal morphology and vascularization of one adult female cougar specimen were observed. The cadaver was identified and positioned in right lateral recumbency. Subsequently, the thorax was opened and dissected to expose the thoracic aorta, into which a No. 6 urethral catheter was inserted. The arterial system was then "flushed" with a 0.9% NaCl saline solution and subsequently fixed with a 10% formalin solution. Afterward, an aqueous solution (1:1 dilution) of Petrolatex S-65 (Refinery Duque de Caxias-REDUC, Petrobrás, Duque de Caxias-RJ) mixed with dye (Suvinil Xadrez®) was injected through the catheter. The cadaver was then immersed in a 50-liter low-density polyethylene container filled with a 10% formalin solution to complete the fixation and polymerization process of the latex.

Seven days after latex injection, the specimen was washed with running water, and the peritoneal cavity was opened and dissected to expose the kidneys. Renal measurements, including length, width, thickness, and ellipsoid volume (Sampaio, 1995), as well as the lengths of the renal arteries and veins, were obtained using a digital caliper (Eda brand).

3 Results and Discussion

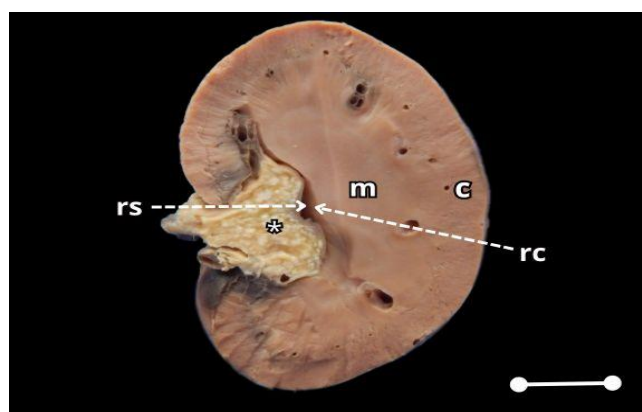
The female's rostro-sacral length was not determined, as the animal arrived without the pelvis. However, its weight was estimated at 27.61 kg. The kidneys presented cranial and caudal extremities, lateral and medial margins (renal hilum), and dorsal and ventral surfaces. The kidneys had a smooth surface, capsular veins, absence of lobulations, and a symmetrical shape. They consisted of an external cortical region and an internal medullary region, with the pelvis and renal crest visible in longitudinal and transverse sections. They were simple and unipapillary (Figures 1 and 2).

Figure 1 - Digital photomacrograph of the transverse section of the cougar kidney. c: renal cortex – m: renal medulla – rs: renal sinus – rs: renal crest – *: renal pelvis. Scale bar: 1 cm



Source: the authors.

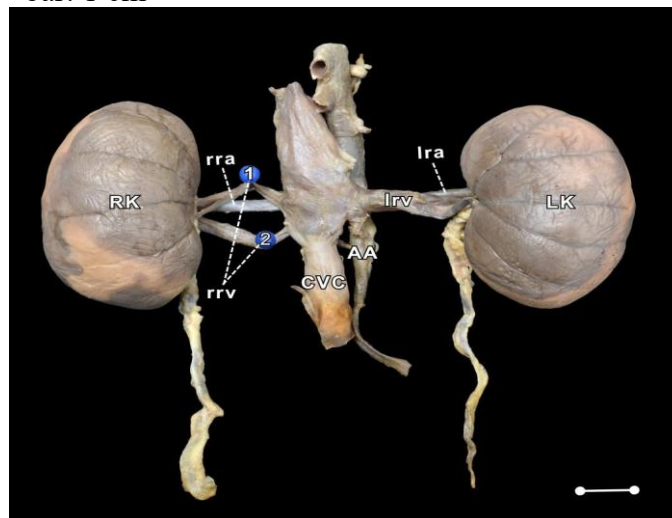
Figure 2 - Digital photomacrograph of the longitudinal section of a puma kidney. c: renal cortex – m: renal medulla – rs: renal sinus – rc: renal crest – *: renal pelvis. Scale bar: 1 cm



Source: the authors.

The right kidney measured 5.51 cm in length, 3.35 cm in width, 3.50 cm in thickness, and had an ellipsoid volume of 33.78 cm³. Due to the condition of the specimen, the kidneys were no longer in their anatomical positions, preventing the determination of skeletopy. The renal artery measured 3.79 cm in length. Two renal veins were observed: the first, craniodorsal, measured 2.80 cm in length, while the second, caudoventral, measured 2.64 cm in length. The left kidney measured 5.39 cm in length, 3.22 cm in width, 3.36 cm in thickness, and had an ellipsoid volume of 32.67 cm³. The renal artery measured 3.04 cm in length. A single renal vein was identified, measuring 2.91 cm in length (Figure 3).

Figure 3 – Digital photomacrograph of the ventral view of the kidneys and renal vessels in the puma. **rk:** right kidney – **lk:** left kidney – **rrv:** right renal veins (¹craniodorsal, ²caudoventral) – **rra:** right renal artery – **ru:** right ureter – **lra:** left renal artery – **lr:** left renal vein – **lu:** left ureter – **aa:** abdominal aorta – **cvc:** caudal vena cava. Scale bar: 1 cm



Source: the authors.

The kidneys of the puma exhibited capsular veins, a smooth surface, and lacked lobation, similar to findings in the domestic cat (Behmanesh; Sorouri, 2024; Martinez *et al.*, 2022; Stocco *et al.*, 2016), the ring-tailed coati (*Nasua nasua*) (Duarte *et al.*, 2022), the crab-eating fox (*Cerdocyon thous*) (Souza Junior *et al.*, 2020), the pampas fox (*Lycalopex gymnocercus*) (Souza *et al.*, 2018), the leopard (*Panthera pardus*) (Chandrasekhar *et al.*, 2015), and the clouded leopard (*Neofelis nebulosa*) (Doley *et al.*, 2015).

In transverse and longitudinal sections, the kidneys presented two distinct regions: the cortex, located peripherally, and the medulla, centrally. They were unipyramidal (unipapillate), in accordance

with the descriptions of Stocco *et al.* (2016) and Martinez *et al.* (2022) for the domestic cat, Duarte *et al.* (2022) for the ring-tailed coati, Souza Junior *et al.* (2020) for the crab-eating fox, Souza *et al.* (2018) for the pampas fox, Chandrasekhar *et al.* (2015) for the leopard, Doley *et al.* (2015) for the clouded leopard, and Jarretta *et al.* (2004) for the small wild cat (*Leopardus guttulus*).

The puma's kidneys measured $5.51 \times 3.35 \times 3.50$ cm (right kidney) and $5.39 \times 3.22 \times 3.36$ cm (left kidney), making them smaller than those of the domestic dog ($60\text{--}90 \times 40\text{--}50 \times 30\text{--}40$ mm) (Evans; De Lahunta, 2013) and the leopard ($7.11 \times 5.35 \times 3.57$ cm (right kidney) and $7.14 \times 4.88 \times 3.37$ cm (left kidney)) (Sarma *et al.*, 2004). However, they were larger than those of other carnivores, including *Nasua nasua* ($30 \times 16 \times 13$ mm) (Duarte *et al.*, 2022), *Lycalopex gymnocercus* ($45 \times 24 \times 21$ mm) (Souza *et al.*, 2018), *Cerdocyon thous* ($43\text{--}55 \times 21\text{--}29 \times 18\text{--}30$ mm) (Souza-Junior *et al.*, 2020), domestic cats ($38 \times 24 \times 23$ mm) (Stocco *et al.*, 2016), and ferrets (*Mustela putorius furo*, $24\text{--}30 \times 12\text{--}13.5 \times 11\text{--}13.5$ mm) (Evans; An, 2014). These differences in renal size among carnivores may be correlated with body size (Duarte *et al.*, 2022).

Renal measurements are relevant for clinical decision-making and serve as indicators of renal functional reserve (Moorthy; Venugopal, 2011). Additionally, morphometric values provide indirect insights into the progression and stability of kidney disease. In renal ultrasonography, end-stage chronic kidney disease in cats typically presents with irregular kidney contours and reduced dimensions (Griffin, 2020). Chronic renal failure is becoming increasingly common in wild felines, particularly those under human care (D'Arcy, 2018; Mitchell; Prozesky; Lawrence, 2018). However, information regarding renal dimensions in species commonly maintained and treated in wildlife medicine remains scarce.

Among renal diseases found in nature, *Diocotophyma renale* parasitism has been reported in *Leopardus pardalis* (Goossen; Nucci; Ayala, 2022) and *Leopardus geoffroyi* (Trindade; Macedo; Muller, 2018). This nematode predominantly affects the right kidney, leading to the destruction of renal parenchyma (Measures, 2001; Pedrassani; Nascimento, 2015). It can be diagnosed via ultrasonography, as it causes changes in renal dimensions and loss of distinction between the cortex and medulla (Mesquita *et al.*, 2014).

The renal measurements presented in this case report may serve as preliminary reference values for interpreting imaging and necropsy findings in pumas. However, these data should be applied cautiously, as the body size of an individual specimen may result in a normal kidney with larger or smaller dimensions than those proposed in this study. For instance, in *C. thous* individuals, kidneys from the southern subpopulation were significantly larger than those from the southeastern population, likely due to differences in body size and diet (Souza Junior *et al.*, 2020).

Regarding vascularization, both kidneys had a single renal artery emerging directly from the abdominal aorta, similar to findings reported by Stocco *et al.* (2016) in domestic cats, Souza *et al.*

(2018) in pampas foxes, Souza Junior *et al.* (2020) in crab-eating foxes, Castano, Ceballos and Tamayo Arango (2022) in pumas, and Duarte *et al.* (2022) in ring-tailed coatis. However, renal artery duplication has been described in domestic cats (Pestana *et al.*, 2011) and in crab-eating foxes (Peçanha *et al.*, 2020). Variations in the number and length of renal arteries are critical factors influencing the success of renal transplantation in felines (Budgeon; Hardie; McAnulty, 2017). In the present report, the lengths of the right and left renal arteries and veins were described. This information is relevant because, according to Budgeon, Hardie and McAnulty (2017), short vessels can complicate surgical procedures. Additionally, even under optimal conditions, their small diameter makes them more susceptible to thrombosis, while imprecise positioning can result in bleeding.

Regarding venous drainage, the renal veins emptied directly into the caudal vena cava, consistent with findings in other carnivores: Stocco *et al.* (2016) in domestic cats, Souza *et al.* (2018) in pampas foxes, Souza Junior *et al.* (2020) in crab-eating foxes, Castano *et al.* (2022) in pumas, and Duarte *et al.* (2022) in ring-tailed coatis. In the puma, the left renal vein was single and longer than the right, measuring 2.91 cm in length. In the right kidney, two renal veins were observed: the first, craniodorsal, measured 2.80 cm, while the second, caudoventral, measured 2.64 cm. In kidney transplants, the left kidney is preferred for donation due to its longer renal vein, which facilitates anastomosis (Gregory *et al.*, 1992; Gregory; Bernstein, 2003; Budgeon, Hardie; McAnulty, 2017).

Variations in renal vein number have been reported in domestic cats (Campos, Rocha; Abidu-Figueiredo, 2014; Stocco *et al.*, 2014), ocelots (*Leopardus pardalis*) (Stocco *et al.*, 2017), small wild cats (*Leopardus guttulus*) (Stocco *et al.*, 2018), ring-tailed coatis (Duarte *et al.*, 2019), and pumas (Castano *et al.*, 2022). These vascular variations have clinical significance, particularly in procedures such as nephrectomy, where failure to identify and properly ligate these vessels before transection poses a high risk of severe hemorrhage (Tillson; Tobias, 2018).

A precise understanding of renal anatomy and its vascularization is crucial for radiological, ultrasonographic, and surgical anatomy and provides valuable insights for clinical treatments in these species. This knowledge is particularly useful for professionals working in zoos and conservation units.

4 Conclusion

The puma's kidneys have a smooth morphology without lobation, similar to other carnivores. Internally, they exhibit a clear distinction between the cortex and medulla, with a unipyramidal architecture. Renal dimensions fall within the range reported for different species, reflecting body size variations. Regarding vascularization, the presence of a single renal artery and the venous drainage pattern align with observations in other carnivores, though variations may occur. These findings contribute to anatomical understanding and support clinical and post-mortem evaluations of

the species. Further studies, particularly with larger sample sizes, are necessary for a more comprehensive characterization of renal anatomy in pumas.

References

- AZEVEDO, F.C. *et al.* Avaliação do risco de extinção da onça-parda *Puma concolor* (Linnaeus, 1771) no Brasil. *Bio. Bras.*, v.3, n.1, p.107-121, 2013. doi: <https://doi.org/10.37002/biodiversidadebrasileira.v3i1.377>
- BELAND, M.D. *et al.* Renal cortical thickness measured at ultrasound: is it better than renal length as an indicator of renal function in chronic kidney disease? *AJR Am J Roentgenol.*, v.195 p.146-149, 2010. doi: <https://doi.org/10.2214/AJR.09.4104>
- BEHMANESH, R.; SOROURI, Z. Radiological assessment of the ratio of kidney length to the length of lumbar vertebrae in cats referred to Tehran-Pet Clinic. *Iran. J. Vet. Surg.*, v.19 n. 2 p.77-81, 2024. doi: <https://doi.org/10.30500/ivsa.2024.424195.1375>
- BUDGEON, C.; HARDIE, R.J.; MCANULTY, J.F. A Carrel patch technique for renal transplantation in cats. *Vet. Surg.*, v.46, n.8 p.1139-1144, 2017. doi: <https://doi.org/10.1111/vsu.12705>
- CAMPOS, C.B.A.; ROCHA, O.S.; ABIDU-FIGUEIREDO, M. Veia renal dupla em gatos: relato de casos. *Rev. Acad. Ciênc. Agrár. Amb.*, v.12, p.127-131, 2014. doi: <https://doi.org/10.7213/academica.12.02.AO06>
- CASTANO, S.M.; CEBALLOS, C.P.; TAMAYO- ARANGO, L.J. Description of the arterial supply and venous drainage of the abdominal viscera in the puma (*Puma concolor*) (Linnaeus, 1771). *Anat Histol Embryol.*, v.51, p.300-307, 2022. doi: <https://doi.org/10.1111/ahe.12770>
- CHANDRASEKHAR, L. *et al.* Gross morphological studies on the kidney of Indian leopard (*Panthera pardus*). *Ind. J. Vet. Anat.*, v.27, n.1, p.57-58, 2015.
- D'ARCY, R. Chronic kidney disease in non- domestic felids in Australian zoos (PhD thesis). University of Sydney, 2018. doi: <http://hdl.handle.net/2123/19610>
- DOLEY, P. *et al.* Gross anatomical studies on the kidneys of clouded leopard. *Ind. J. Vet. Anat.*, v.27, n.1, p.59-60, 2015. doi: <https://epubs.icar.org.in/index.php/IJVA/article/view/49641>
- DUARTE, R.D. *et al.* Morfometria e esqueletoptia dos rins e vasos renais no "quati de cauda anelada" (*Nasua nasua*). *Ciênc. Anim. Bras.*, v.23, p.1-8, 2022. doi: <https://doi.org/10.1590/1809-6891v23e-72329E>
- DUARTE, R.D. *et al.* Veia renal direita dupla em quati (*Nasua nasua*, Linnaeus) - relato de caso. *Rev. Ciênc. Vet. Saúde Pública*, v.6, n.2, p.371-377, 2019. doi: <http://dx.doi.org/10.4025/revcivet.v6i2.45894>
- EVANS, H.E.; DE LAHUNTA, A. *Miller's anatomy of the dog*. St. Louis: Saunders Elsevier, 2013.
- EVANS, H.; AN, Q.N. *Anatomy of the ferret*. In: FOX, J.G.; MARINI, R.P. *Biology and diseases of the ferret*. Oxford: Wiley Blackwell, 2014. p.23-68.
- GOOSSEN, T.S.; DI NUCCI, D.L.; AYALA, D.A. A rare case of ectopic dioctophymosis in *Leopardus pardalis* (Carnivora, Felidae) in Paraguay. *Vet. Parasitol. Regi. Stud. Rep.*, v.27, p.106-111, 2022. doi: <https://doi.org/10.1016/j.vprsr.2021.100657>
- GREGORY, C.R.; BERNSTEEN, L. Transplante de órgãos na prática clínica veterinária. In: SLATTER D. *Livro-texto de cirurgia de pequenos animais*. Filadélfia: Saunders; 2003. p.122-136.
- GREGORY, C.R. *et al.* Renal transplantation for treatment of end-stage renal failure in cats. *J. Am. Vet. Med. Assoc.*, v. 201, p.285-291, 1992.

GRIFFIN, S. Feline abdominal ultrasonography: What's normal? What's abnormal? The kidneys and perinephric space. J. Feline Med. Surg., v.22, p.409-427, 2020. doi: <https://doi.org/10.1177/1098612X20917598>

HESPEL, A.M.; LEON, J.; DUVAL, A. Radiologic measurement and determination of Kidney-to-vertebra ratios as a method of estimating renal size in servals (*Leptailurus serval*). J. Zoo. Wildl. Med., v.50, n.3, p.589-593, 2019. doi: <https://doi.org/10.1638/2018-0168>

JARRETTA, G.B.; BOMBONATO, P.P.; GUIMARÃES, M.A. Renal ultrasonographic evaluation in the onçilla (*Leopardus tigrinus*). J Zoo Wildl Med., v. 35, n. 3, p. 356-60, 2004. doi: <https://doi.org/10.1638/02-021>

MARTINEZ, M.; SOLER, M.; LAREDO, F.G.; BELDA, E.; AGUT, A. Ultrasonographic assessment of the renal size using a kidney length to vertebral body length ratio in cats. Front Vet Sci., v.9, p.887746, 2022. doi: <https://doi.org/10.3389/fvets.2022.887746>

MEASURES, L.N. Dioctophymatosis. In: SAMUEL, W.M; PYBUS, M.J.; KOCAN, A.A. Parasitic diseases of wild mammals Ames: Iowa State University Press; 2001. p.357-364. doi: <http://dx.doi.org/10.1002/9780470377000.ch13>

MESQUITA, L.R. et al. Pre- and post-operative evaluations of eight dogs following right nephrectomy due to Dioctophyma renale. Vet Q., v.34, n.3, p.167-171, 2014. doi: <http://dx.doi.org/10.1080/01652176.2014.924166> PMID:24832362

MITCHELL, E.P.; PROZESKY, L.; LAWRENCE, J. A new perspective on the pathogenesis of chronic renal disease in captive cheetahs (*Acinonyx jubatus*). PLoS One, v.13, n.3, p.e0194114, 2018. doi: <https://doi.org/10.1371/journal.pone.0194114>

MOELL, H. Size of normal kidneys. Acta Radiol., v. 46, p.640-645, 1956.

MOORTHY, H.K.; VENUGOPAL, P. Measurement of renal dimensions in vivo: a critical appraisal. Ind. J. Urol., v.27, p.169-175, 2011. doi: <https://doi.org/10.4103/0970-1591.82832>

NICKEL, R.; SCHUMMER, A.; SEIFERLE, E. The anatomy of the domestic animals. Berlin: Verlag Paul Parey, 1981.

OLIVEIRA, T.G.; CASSARO, K. Guia de identificação dos felinos brasileiros. São Paulo: Sociedade de Zoológicos do Brasil, 1999.

PEÇANHA, S.V. et al. Double renal artery in *Cercopithecus thomasi*. Revista MVZ Córdoba, v. 25, n. 1, p. 1713-1718, 2020. doi: <https://doi.org/10.21897/rmvz.1713>

PEDRASSANI, D.; NASCIMENTO, A.A. Verme gigante renal. Rev. Port. Ciênc. Vet., v.110, p.30-37, 2015.

PESTANA, F.M. et al. Artéria renal dupla em gato. Semina Ciênc. Agrár., v.32, n.1, p.327-332, 2011. doi: <https://doi.org/10.5433/1679-0359.2011v32n1p327>

SAMPAIO, F.J. Theoretical kidney volume versus real kidney volume: comparative evaluation in fetuses. Surg. Radiol. Anat., v.17, p.71-75, 1995. doi: <https://doi.org/10.1007/BF01629504>

SARMA, K.; ZAMA, M.; SURU, S.; KALITA, A. Macromorphological study on the kidney of leopard (*Panthera pardus*). Ind. J. Anim. Sci., v.74, p.1137-1138, 2004. <https://www.researchgate.net/publication/294224399>

SOUZA, E.C. et al. Caracterización anatómica de los riñones del zorro pampeano (*Lycalopex gymnocercus*): morfometría y vasos renales. Rev Electr. Vet., v.19, p.1-8, 2018.

Ensaio e Ciência, v.29, n.1, p.105-114, 2025

SOUZA-JUNIOR, P. *et al.* Dimensions and skeletopy of kidneys in two populations of *Cerdocyon thous* (Linnaeus, 1766). Acta Vet. Bras., v.14, p.106-114, 2020. doi: <https://doi.org/10.21708/avb.2020.14.2.9126>

STOCCO, A.V. *et al.* Duplicidade da veia renal direita em gato-do-mato-pequeno (*Leopardus guttulus*): relato de caso. Rev. Acad. Ciênc. Anim., v.16, p.1-6, 2018. <https://doi.org/10.7213/academica.16.2018.01>

STOCCO, A.V. *et al.* Is there a difference between the right and left kidney? A macroscopic approach in Brazilian Shorthair Cat. Arq. Bras. Med. Vet. Zootec., v.68, p.1137-1144, 2016. doi: <https://doi.org/10.1590/1678-4162-8339>

STOCCO, A.V. *et al.* Veia renal direita dupla em jaguatirica (*Leopardus pardalis*): relato de caso. Rev. Port. Ciênc. Vet., v.112, p 83-86, 2017.

STOCCO, A.V. *et al.* Veia renal tripla em gato: relato de casos. Revista Portuguesa de Ciências Veterinárias, v.109, p.120-122, 2014. doi: <https://doi.org/10.7213/academica.12.02.AO06>

SUNQUIST, M.E.; SUNQUIST, F.C. Family Felidae (cats). In: WILSON, D.E.; MITTERMEIER, R.A. The mammals of the world. Vol. 1. Carnivores. Lynx Editions, 2009. p.54-186.

TILLSON, D.M.; TOBIAS, K.M. Kidneys. In: Veterinary Surgery: Small Animals, Saunders; 2018. p. 1944-1961.

TRINDADE, M.A.C.; MACEDO, M.R.P.; MULLER, G. *Diectophyme renale* (Nematoda: Dioctophymatidae) in *Leopardus geoffroyi* (Carnivora: Felidae) in the Neotropical region. Rev Bras. Parasitol. Vet., v.27, n.2, p.223-225, 2018. doi: <https://doi.org/10.1590/S1984-29612017079>

YAMASHITA, S.R. *et al.* Value of renal cortical thickness as a predictor of renal function impairment in chronic renal disease patients. Radiol Bras., v. 48, n. 1, p.12-6, 2015. doi: <https://doi.org/10.1590/0100-3984.2014.0008>