




DOI: [10.17921/1415-6938.2025v29n2p292-298](https://doi.org/10.17921/1415-6938.2025v29n2p292-298)


Visual Diagnosis of Jaundice in Pigs: an Anatomopathological Approach for *post-Mortem* Inspection


Diagnóstico Visual da Icterícia em Suínos: uma abordagem Anatomopatológica para Inspeção *Post-Mortem*

Received on: 22/11/2024


Accepted on: 04/03/2025


Guilherme Augusto Dillenburg Destri: Universidade Paranaense, Programa de Pós-Graduação em Ciência Animal com Ênfase em Produtos Bioativos. PR, Brazil. E-mail: guilherme200691@edu.unipar.br. 

Maria da Conceição Gonçalves Macêdo: Universidade Federal da Paraíba, Programa de Pós-Graduação em Ciência Animal. PB, Brazil. 

Camila de Cuffa Matusaiki: Universidade Paranaense, Programa de Pós-Graduação em Ciência Animal com Ênfase em Produtos Bioativos. PR, Brazil. 

Rafael Silva Tarifa Navarro: Universidade Paranaense. PR, Brazil. 

Victor Hugo Cortez Dias: Universidade Paranaense. PR, Brazil. 

Luciana Kazue Otutumi: Universidade Paranaense, Programa de Pós-Graduação em Ciência Animal com Ênfase em Produtos Bioativos. PR, Brazil. 

Abstract

Jaundice is a pathological pigmentation resulting from pre-hepatic, hepatic or post-hepatic disorders, characterized by disarray in bile flow and consequent hyperbilirubinemia. This condition causes yellowish coloration in specific tissues of the carcass, especially those containing elastic fibers. During *post-mortem* inspection of pigs, color assessment is predominantly visual, which can lead to subjective interpretations among the professionals responsible for judging the carcass. This study proposes a visual method based on the comparison of the coloration of the arteries adjacent to the brachial plexus, aiming to aid in the diagnosis of jaundice without the need for chemical reagents. During the study period, the prevalence of jaundiced carcasses was 0.06% in relation to the total volume slaughtered, representing 1.2% of the deviations forwarded to the Final Inspection Department. It is concluded that visual comparison of the brachial plexus arteries between suspect and non-suspect carcasses can contribute to a more accurate decision in the final inspection, reducing the need for handling chemical substances.

Keywords: Carcass. Liver Diseases. Tissue Staining. Vascular Endothelium. Food Inspection.

Resumo

A icterícia é uma pigmentação patológica resultante de distúrbios pré-hepáticos, hepáticos ou pós-hepáticos, caracterizados pelo desarranjo no fluxo biliar e consequente hiperbilirrubinemia. Essa condição provoca a coloração amarelada em tecidos específicos da carcaça, especialmente aqueles que contêm fibras elásticas. Durante a inspeção *post-mortem* de suínos, a avaliação da coloração é predominantemente visual, o que pode levar a interpretações subjetivas entre os profissionais responsáveis pelo julgamento da carcaça. Este estudo propõe um método visual baseado na comparação da coloração das artérias adjacentes ao plexo braquial, visando auxiliar no diagnóstico de icterícia sem a necessidade de reagentes químicos. Durante o período do estudo, a prevalência de carcaças ictericas foi de 0,06% em relação ao volume total abatido, representando 1,2% dos desvios encaminhados ao Departamento de Inspeção Final. Conclui-se que a comparação visual das artérias do plexo braquial entre carcaças suspeitas e não suspeitas pode contribuir para uma decisão mais precisa na inspeção final, reduzindo a necessidade de manipulação de substâncias químicas.

Palavras-chave: Carcaça. Hepatopatias. Coloração de Tecidos. Endotélio Vascular. Inspeção de Alimentos.

1 Introduction

According to current Brazilian legislation, represented by the Ministry of Agriculture, Livestock, and Supply (Brazil, 2017), all carcasses and their respective organs must be evaluated for their most appropriate destination during post-mortem inspection. The regulation highlights various alterations as grounds for total condemnation, including those that affect the general condition of the carcass, such as emaciation, cachexia, inflammatory or circulatory changes, and alterations in color or odor.

In this context, Barros (2016) describes jaundice as a significant discoloration, characterized by yellowing of the tissues due to hyperbilirubinemia, which may result from hemolysis, liver dysfunction, or cholestasis. The intensity of the discoloration, according to Kelly (2002), may be related to the severity and duration of biliary obstruction, being more noticeable in cases of moderate cholestasis than in acute liver failure. In addition to indicating possible systemic changes, the author notes that jaundice directly affects the product consumer acceptance, emphasizing its importance not only from a sanitary standpoint but also from an economic perspective.

Rimington and Fourie (1934) presented a rapid analytical test adapted for identifying jaundice in carcasses. This method involves heating fat aliquots in a sodium hydroxide solution, followed by cooling and ether addition, promoting the separation of bile pigments and carotenoids present in the fat. Despite its effectiveness, the method may be operationally limiting due to time and resource constraints.

Since post-mortem inspection of pigs still faces challenges - especially regarding the visual evaluation of carcass coloration due to subjective criteria - this study proposes an alternative visual method based on the comparative analysis of the coloration of arteries adjacent to the brachial plexus. This is intended as a practical and accessible tool to assist in the diagnosis of jaundice in swine

carcasses, as a substitute for chemical testing.

2 Material and Methods

The study was conducted at the Final Inspection Department (DIF) of a pig slaughterhouse under the supervision of the State Inspection Service of Paraná for Products of Animal Origin (SIP/POA), which is accredited by the Brazilian System for the Inspection of Products of Animal Origin (SISBI/POA). The facility is located in the city of Toledo, in the western region of the state of Paraná, and the study was carried out from May to December 2022. During this period, 8,687 pig carcasses were evaluated on the post-mortem inspection line. The anatomopathological analysis was performed by a single trained evaluator specialized in post-mortem pig inspection, aiming to minimize interpretation bias.

The procedure consisted of extracting and evaluating the coloration of arteries adjacent to the brachial plexus that had been redirected to the DIF due to suspected discoloration during official inspection.

For the exposure and removal of blood vessels, a hook, a steel mesh glove, and a stainless-steel knife were used. Initially, a transverse cut was made immediately after the scapula to allow the thoracic limb to be pulled down, exposing the brachial plexus. From this anatomical region, an artery sample was collected. The same procedure was performed for collecting arteries from carcasses deemed free of pathological discoloration by official inspection.

Subsequently, both discolored and normal arteries were sectioned for visual observation of the vascular endothelium. Ambient lighting was maintained above 540 lux, as required by Brazil (1995), to ensure appropriate conditions for evaluating internal artery coloration.

Descriptive statistics for jaundice cases from May to December 2022 were performed by calculating absolute and relative frequencies (%). Data regarding carcasses redirected to the Final Inspection Department and the slaughter volume during the period were organized and tabulated using Microsoft Excel® 2016.

3 Results and Discussion

Considering the total number of carcasses recorded at the DIF, regardless of the judgment rendered, this study found that 5.78% of the slaughtered carcasses were subject to some form of condemnation, either partial or total. These values are lower than those observed in the data survey from the Federal Inspection Service Information Management System (SIGSIF) between 2012 and 2017, conducted by Silva *et al.* (2020), which found an average of 10.1% condemnation among pig carcasses redirected to the Final Inspection Department. Conversely and Cória (2021) reported an even lower percentage, with 3.22% of total and partial condemnations. These variations may be

attributed to differences in production systems and the sanitary conditions of swine herds in different regions.

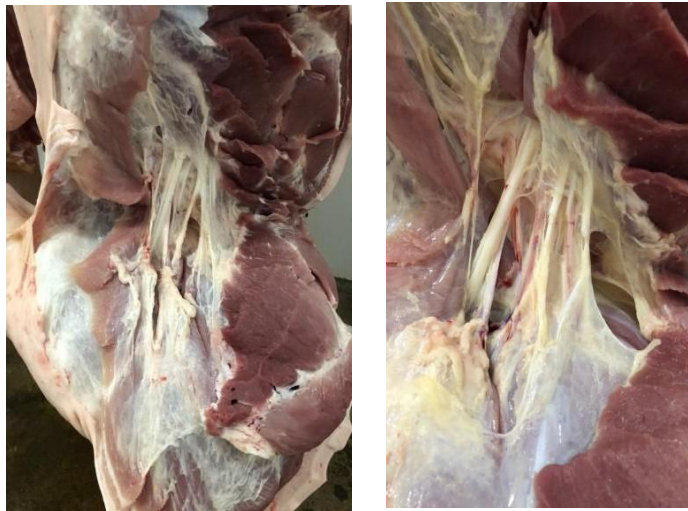According to Silva *et al.* (2020), the main causes of condemnation include: adhesions, contamination, bruising, pleurisy, abscesses, lymphadenitis, pneumonia, cryptorchidism, suppurative lesions, and other statistically less relevant causes. The present study found similar and additional occurrences, including: abscesses, contamination due to technological failure, adhesions, arthritis, fractures, pleurisy, bruising, adenitis, peritonitis, dermatitis, pleuropneumonia, jaundice, umbilical phlebitis, non-complicated hernias, cachexia, repugnant appearance, metritis, mastitis, erysipelas, congestion, polyserositis, generalized edema, septicemia, anemia, emaciation, and endocarditis.

Coldebella *et al.* (2018), analyzing SIGSIF data from 2012 to 2014, identified other reasons for pig carcass condemnation in addition to the aforementioned ones, such as dermatitis, arthritis, enteritis, jaundice, endocarditis, hernias (with or without carcass impact), anemia, erysipelas, emaciation/cachexia, peritonitis, serositis, and technological failures during slaughter.

Some changes in the general condition of the carcass can be subtle, especially those related to tissue coloration, which may cause uncertainty in judgment during post-mortem inspection. Regarding jaundice, the prevalence of condemnations was 0.06%, higher than the 0.003% reported by Coldebella *et al.* (2018) and 0.01% reported by Filippini and Freitas (2021). This discrepancy may be associated with the quality of the raw material received by the slaughterhouse.

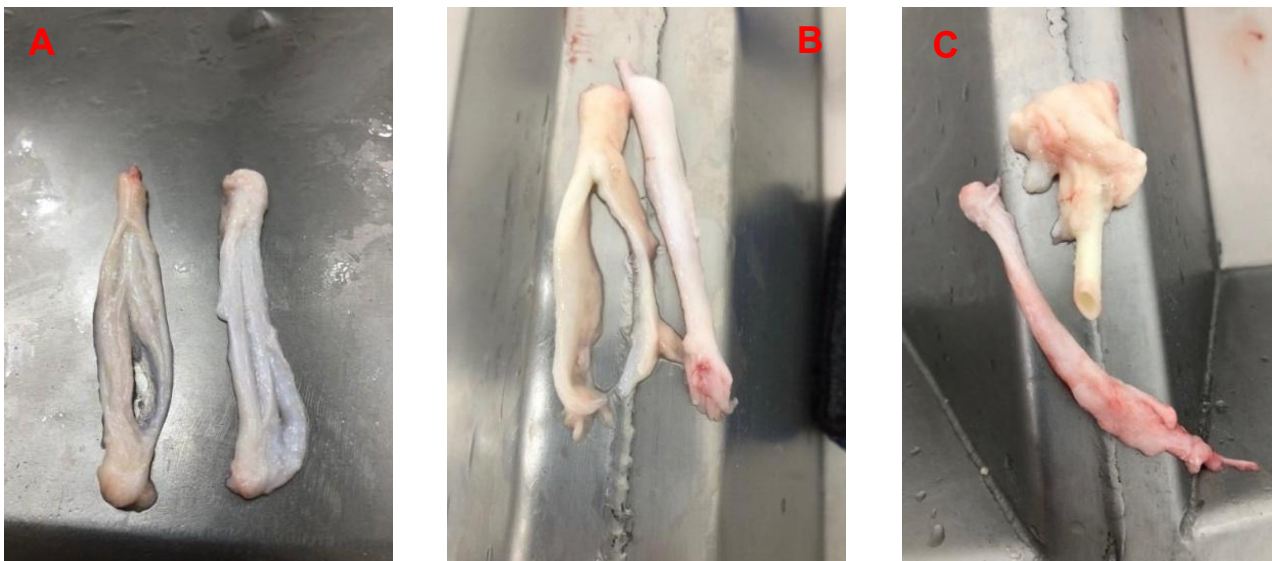During the evaluation period, 93 carcasses were condemned due to jaundice, representing 1.2% of those referred to DIF. The application of the proposed method - exposing the blood vessels adjacent to the brachial plexus (Figure 1) - revealed varying degrees of yellow pigmentation, ranging from mild to intense (Figure 2), confirming the correlation between color intensity and severity of cholestasis, as described by Kelly (2002). The pathological findings align with Smith (2015), who describes bilirubin ability to pigment tissues rich in elastic fibers, such as the auricular pinna, vocal cords, epiglottis, lungs, nuchal ligament, dermis, aorta, and muscular arteries - structures capable of expanding up to 2.5 times their original size.

Figure 1 - (A) Retraction of the thoracic limb and (B) exposure of blood vessels adjacent to the brachial plexus in swine carcasses



Source: the authors.

Figure 2 - Comparative visual analysis of blood vessels from carcasses with suspected jaundice (yellowish color) and without suspected jaundice (whitish color), showing varying intensities of pathological pigmentation: (A) mild, (B) moderate, and (C) intense



Source: the authors (2022).

Eurell and Sickle (2012) state that this condition facilitates bilirubin diffusion through artery walls, as they distend due to increased pressure from blood pumping in cases of hyperbilirubinemia. According to Frappier (2012), bile canaliculi are formed by cell membranes with short microvilli, which prevent bile leakage into the interstitial space surrounding the canaliculi.

Comparing artery coloration can help rule out false positives, such as adipoxanthosis. According to Wilson (2009), this condition results from pigments in the animal's diet and is restricted exclusively to adipose tissue, without affecting other tissues. The author notes that adipoxanthosis is

more common in cattle, particularly in Jersey and Guernsey breeds, as well as in aged cows. According to Brazil (2017), this condition does not require special judgment, and the affected carcasses may be approved.

4 Conclusion

The evaluation of the coloration of blood vessels adjacent to the brachial plexus proved to be a potentially effective tool for identifying jaundice in swine carcasses, offering a practical alternative to laboratory analysis without requiring specific environments or chemical handling. When applied under lighting conditions required by legislation, this technique can optimize post-mortem inspection of pigs at all jurisdictional levels (federal, state, and municipal), promoting greater standardization in carcass judgment and contributing to reduced use of chemical reagents. Further research is needed to validate the technique as a definitive alternative to chemical testing, especially under different operational conditions and inspection settings.

References

- BARROS, C.S.L. Fígado, vias biliares e pâncreas exócrino. In: SANTOS, R.L.; ALESSI, A.C. Patologia veterinária. Rio de Janeiro: Roca, 2016.
- BRASIL. Ministério da Agricultura, Pecuária e Abastecimento. Portaria n.º 711, de 1º de novembro de 1995. Aprova as normas técnicas de instalações e equipamentos para abate e industrialização de suínos. Diário Oficial da União: seção 1, Brasília: MS, 1995.
- BRASIL. Decreto n.º 9.013, de 29 de março de 2017. Aprova o Regulamento da Inspeção Industrial e Sanitária de Produtos de Origem Animal (RIISPOA). Diário Oficial da União: seção 1, Brasília, DF, 30 mar. 2017.
- COLDEBELLA, A. *et al.* Avaliação dos dados de abate e condenações/desvios de suínos registrados no sistema de informações gerenciais do serviço de inspeção federal nos anos de 2012 a 2014. Concórdia: Embrapa Suínos e Aves, 2018.
- CÓRIA, A.D. Condenações em frigorífico de suínos no Vale do Itajaí/SC. Curitiba: Universidade Federal de Santa Catarina, 2021.
- EURELL, J.A.; SICKLE, D.C. Tecidos conjuntivos e de sustentação. In: EURELL, J.A.; BRIAN, L. Histologia veterinária de Dellmann. Barueri: Manole, 2012.
- FILIPPINI, V.; FREITAS, E. S. Frequência de condenação de vísceras e carcaças de suínos abatidos no ano de 2018 em um frigorífico localizado na região oeste do Paraná. Arq. Bras. Med. Vet., v.4, n.1, 2021.
- FRAPPIER, B.L. Sistema digestivo. In: EURELL, J.A.; BRIAN, L. Histologia veterinária de Dellmann. Barueri: Manole, 2012.
- KELLY, W.R. Enfermedad del hígado en grande y pequenos ruminantes. In: JORNADA

URUGUAYAS DE BUIATRÍA, 30.; CONGRESSO LATINOAMERICANO DE BUIATRÍA, 10. Anais [...]. Paysandú, Uruguai, p. 1-6, 2002.

RIMINGTON, C.; FOURIE, P. J. J. A rapid phase test for distinguishing between carotinoid and bile staining of fat in carcasses. Onderstepoort J. Vet. Sci. Animal Ind., v.10, n.2, p.439-441, 1938.

SILVA, E.C. *et al.* Análise de condenações de carcaça ao abate de suínos em abatedouros frigoríficos brasileiros registrados no serviço brasileiro de inspeção federal entre 2012 e 2017. Rev. Bras. Multidisc., v.23, n.3, 2020.

SMITH, B. P. Large animal internal medicine. St. Louis: Elsevier, 2015.

WILSON, W. G. Wilson's inspeção prática da carne. São Paulo: Roca, 2009.